

Tissue Management with the Nd:YAG Laser: A Clinical Report



Raffaello Cimma^a, Marco Cravero^b, Giovanni Anglesio Farina^c, Eraldo Pomatto^d

^a Dentist in Private Practice, Torino, Italy.

^b Dentist in Private Practice, Sanfre' Cuneo, Italy.

^c Dentist in Private Practice, Bruino, Italy.

^d Dentist in Private Practice, Torino, Italy.

Purpose: The purpose of this preliminary report was to verify the potential of the Nd:YAG laser as a retraction device used in combination with retraction cords.

Materials and Methods: The use of the Nd:YAG laser as a retraction device was evaluated in a clinical trial on eight selected patients, with 54 teeth involved, in 1 year. All required endodontic treatment and some needed periodontal surgery before prosthetic treatment. All patients were followed up for one year. Plaque index, bleeding on probing, and gingival sulcus depth on probing were checked.

Results: The soft tissue always showed optimum health after 10 days of the treatment. The main advantages are: use of only topical anesthetic, bleeding control, short healing time, operative and postoperative absence of pain.

Conclusion: Nd:YAG lasers show great potential for prosthetic use, but other investigations on buccal gingival retraction will be necessary in order to study the level of permanent tissue recession using Nd:YAG laser without mechanical retraction.

Keywords: Nd:YAG laser; retraction device; fixed crowns; impressions; gingival margins.

J Oral-Laser Applications; 2007; 7: 107-113.

Submitted for publication: 06.02.06; accepted for publication: 05.02.07.

The relationship between a fixed prosthesis and the surrounding soft and hard tissue are crucial for long-term success. The majority of clinical situations requires restoration with subgingival margins;¹ therefore, fixed crowns require an accurate impression that records the location of the finish line of the prepared teeth and a portion of nonprepared tooth structure.^{2,3} It is thus necessary to effectively displace the free gingival margins. Various methods and techniques have been described in the literature to achieve exposure of the finish line and create an acceptable environment for impression materials: mechanical methods, mechanochemical methods, rotary gingival curettage or gingivage, electrosurgery, lasers, and modified custom tray.⁴⁻¹⁰ A great number of studies reported complete

tissue healing after gingival retraction without permanent damage of the soft tissues,¹¹⁻¹⁴ but other studies reported permanent gingival damage associated with retraction procedures.¹⁵⁻²² One of the newest applications for dental lasers is soft-tissue management. The Nd:YAG laser (Nd:YAG Smarty A.10, DEKA M.E.L.A.; Florence Italy) was selected because it is already commonly used in a number of clinical situations in dentistry and in general surgery, and, most importantly, because it provides optimum bleeding control. The following study offers a preliminary evaluation of the effects of the Nd:YAG laser used as a retraction device on soft tissue, immediately after impressions and during follow-up.

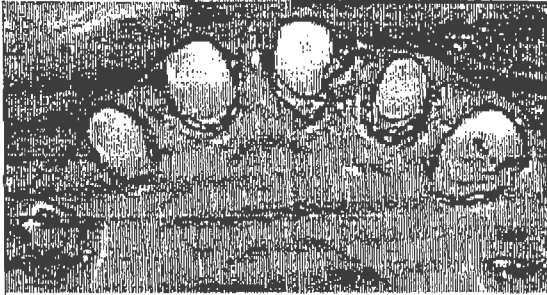


Fig 1. Maxillary incisors and canines of the first patient group, after treatment on the interproximal and palatal sides.

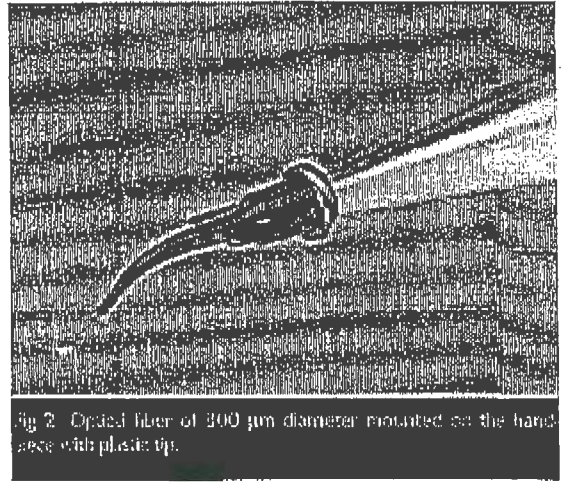


Fig 2. Optical fiber of 300 μ m diameter mounted on the handpiece with plastic tip.

MATERIALS AND METHODS

In 1 year, 2 patient groups in good general health were treated after signing a consent form. All patients of the 2 groups needed periodontal surgery, and were reevaluated at the end of tissue healing. Finally, only 7 patients remained and these were divided into 2 groups. The first group involved 4 patients with 31 teeth: all these patients were selected with the following criteria: (1) plaque index "0", absence of plaque accumulation; (2) gingival sulcus depth between 0.5 and 1.5 mm; (3) no bleeding on probing. The second group involved 3 patients with 23 teeth: they were selected with similar criteria but at the moment of impression taking, moderate bleeding and seepage on probing in some zones of gingival sulcus occurred. The age of the patients ranged from 30 to 57 years. A total of 54 teeth were involved: 11 maxillary incisors and 5 canines, 10 maxillary premolars, 10 maxillary molars; 4 mandibular canines, 9 mandibular premolars, and 5 mandibular molars. All patients received porcelain-fused-to-metal crown restorations and they were followed up each month for one year. During this time period, the probing attachment level (PAL), bleeding on probing (BOP), plaque index (PI) and gingival recession (REC) were initially recorded immediately before impressions as a baseline and during periodic maintenance appointments (Tables 1 and 2). The data were statistically analyzed with the Student t-test.

To best control the depth of penetration, the laser was used in contact mode with continuous air flow. Because the literature contains only general information on laser parameters for this indication,^{14,23-25} the

Nd:YAG laser parameters in this study were set at 3.20 W, 80 Hz, and 40 mJ, as recommended by the manufacturer for gingival retraction (Fig 1). Nd:YAG laser irradiation is delivered through an optical fiber, and it is possible to choose different diameters from 200 to 600 μ m. We used a 300- μ m fiber mounted in a handpiece that allowed easy access in all parts of the mouth (Fig 2).

Clinical treatment

Endodontic treatment was performed in all patients. The teeth were initially prepared at the gingival level, and temporary crowns lined with acrylic resin were inserted. In group 2, periodontal surgery was also performed. The final preparation of teeth and relining of temporary crowns with acrylic resin was done after two weeks. After 120 days, in order to obtain complete gingival healing and tissue stability,^{5,6} impressions were made (Fig 3). During this period, the patients were checked each month, and ten days before impression taking, a final periodontal check-up was done. A gingival finish line was prepared within the intracrevicular space during the impression appointment with help of magnifying loupes, taking the greatest possible care to avoid injury to gingival tissue. Before topical anesthesia with lidocaine, Nd:YAG laser was used on all tooth aspects except the buccal side of the incisors, canines, premolars, and nine of the maxillary molars, while it was used on all sides of the mandibular molar and one maxillary molar.

Table 1 Baseline and 1-year clinical measurements of first patient group

Tooth no.	Baseline			1 yr			REC
	PAL	BOP	PI	PAL	BOP	PI	
33	1	0	0	1	0	0	\
35	1	0	0	1	0	0	\
36	2	1	0	3	1	1	0.3
43	1	0	0	1	0	0	0.2
44	1	0	0	1.5	0	0	0.2
11	0.5	0	0	0.5	0	0	\
12	0.5	0	0	0.5	0	0	\
13	0.5	0	0	0.5	0	0	\
14	1	0	0	0.5	0	0	\
17	1	1	1	1	1	0	\
21	0.5	0	0	0.5	0	0	\
22	0.5	0	0	0.5	0	0	\
11	1	0	0	1.2	0	0	\
12	1	0	0	1.2	0	0	\
14	1	0	0	1.2	0	0	\
15	1	0	0	1.2	0	0	\
21	1	0	0	1.2	0	0	\
11	0.7	0	0	1	0	0	\
12	0.7	0	0	1	1	0	\
13	0.7	0	0	1	0	0	\
15	0.5	0	0	0.5	0	0	\
16	1	0	0	1	0	0	\
21	0.7	0	0	1	0	0	\
22	0.7	0	0	1	0	0	\
23	0.7	0	0	1	0	0	\
26	1	1	1	1	1	0	\
35	0.5	1	0	0.5	0	0	\
37	1	1	0	1	0	1	0.3
44	0.5	1	0	0.5	0	0	0.2
45	0.5	1	1	0.5	0	0	0.2
47	1	1	0	1	1	0	0.3

PAL: probing attachment level; BOP: bleeding on probing; P1: plaque index; REC: gingival recession.

The laser was used only in contact mode with a sweeping motion and a "dragging" movement. It was essential not to stop or stay too long in the same area, in order to prevent damaging the tissue and let this area cool, returning after a short while. It is also important to use only the tip of the fiberoptic laser and to keep the tissue dry with a continuous cool air jet. These operations are needed to safeguard gingival tissue and to avoid heat dispersion into the tissue. The displacement of tissue with retraction cords on all sides of the intracrevicular space was completed (Figs 4 and 5) on all teeth except for 2 mandibular molars. After

about 30 to 40 min, impressions were made with polyether and a modified custom tray.¹⁶ The final porcelain-fused-to-metal crowns were cemented 45 to 60 days later. This time was needed in order to carry out necessary dental technician work and clinical controls of crown precision.

RESULTS

The statistical analysis revealed no statistically significant changes in BOP and PI, whereas there was a little variation in PAL (Table 3).

Table 2 Baseline and 1-year clinical measurements for the second patient group

Tooth no.	Baseline			1 yr			REC
	PAL	BOP	PI	PAL	BOP	PI	
24	1	1	0	1	0	0	\
26	1.5	1	0	1.5	0	0	\
27	1.5	1-2	1	1.5	1	1	0.2
13	0.5	1	0	1	0	0	\
14	1	1	0	1	0	0	\
15	1	1	0	1	0	0	\
17	1	1	1	1	1	1	\
23	0.5	1	0	0.7	0	0	\
24	0.5	1	0	0.7	0	0	\
25	1	1	1	1	0	0	\
26	1	1	0	1	0	0	\
27	1	1	0	1	0	0	\
33	0.5	1	1	0.7	0	0	\
34	0.5	0	0	0.7	0	0	\
35	0.5	0	0	0.7	0	0	\
36	0.5	0	0	0.7	2	0	0.2
43	0.5	0	0	0.7	0	0	0.2
44	1	0	0	1	0	0	0.2
45	0.5	0	0	0.7	0	1	\
47	1	0	1	1	0	0	0.3
15	1	1	0	1	0	0	\
16	1.5	1	0	1.5	0	0	\
17	1.5	1	0	1.2	0	0	\

Table 3 Student's t-test of data from all patients, comparing baseline and 1-year measurement of bleeding upon probing, plaque index and probing attachment.


Variable	N	Mean D	SD	T	p
BOP	54	-0.24	0.59109	-2.98369	0.006026
PI	54	-0.33333	0.516398	-4.74311619	0.000028
PAL	54	0.103704	0.209188	3.64296	0.000614

Postsurgical complications such as infections, inflammatory reactions, or blood clots were not observed. There was rapid tissue healing within ca 10 days (Figs 6 and 7), with little pain or, in a majority of cases, absence of pain. The soft tissue completely recovered within this time, except the buccal aspects of the six molars (five mandibular molars and one maxillary

molar were treated). After healing was complete, the buccal part of the molars treated with laser showed permanent tissue recession up to 0.2 to 0.3 mm that did not resolve during the follow-up period. On the two mandibular molars which were gingivally treated with laser alone, it was necessary to repeat impression taking, because there was not sufficient space to apply



Fig 3 One maxillary premolar and two molars of the second patient group before impression taking, ca 120 days after periodontal surgery. A small zone with moderate bleeding and seepage is evident.



4 Tissue displacement completed with retraction around all sides of the maxillary teeth.



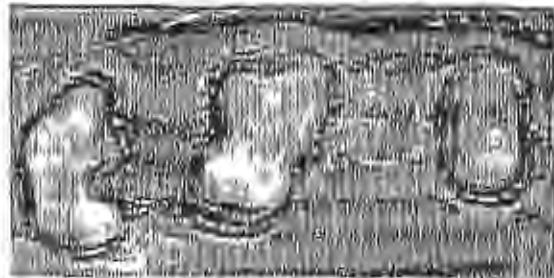Fig 5 Gingival retraction with cords completed.



Fig 6 Soft tissue healing after 7 days.




Fig 7 Detail of the soft tissue healing of the first and second maxillary molars, after 10 days.



8 Nd:YAG laser troughing of the gingival tissue completed the retraction procedure. Notice absence of bleeding.

a good bulk of Impression material near the finish line of the teeth.

DISCUSSION

The Nd:YAG lasers were developed in 1964.¹⁴ They are lasers in the infrared range of the spectrum (1,064 μm), and thus their light cannot be seen. Therefore, a red helium-neon spot light for aiming is used. Like all lasers, the light is coherent, monochromatic, and collimated. Nd:YAG laser radiation is absorbed by pigmented tissue, chiefly hemoglobin and melanin. Therefore it is highly recommended not to work with tissue accumulation on the tip, in order to avoid heat scattering on the gingival tissue. A small part of laser radiation is absorbed by water; moreover, there is radiation refraction in the water. A combination of these two phenomena causes a dissipation of energy with damaging effects on tissues. Energy is emitted in pulsed mode, and penetrates to a depth in tissues of 0.5 to 1 mm.

This preliminary study focused on the final impressions of multiple abutments with the use of Nd:YAG laser and retraction cords as gingival retraction devices.

The effects of Nd:YAG laser radiation on tissues include optical coagulation, optical scattering, and cell vaporization. Lasers can be used to create a sulcus around a tooth before an impression is taken. To try to minimize gingival damage, the laser was used in combination with the mechanical method of gingival displacement. This combination of Nd:YAG lasers and the mechanical method allows us to have an optimum control of soft tissue, particularly in cases involving multiple abutments and when the sulcus is too shallow to use only retraction cords. This combination is also important because it allows gingival tissue displacement both laterally and vertically. Lateral retraction displaces the tissue so that an adequate bulk of impression material can be interfaced with the prepared teeth.^{8,18}

With careful use of the Nd:YAG laser, remarkable seepage and bleeding control of the gingival sulcus is possible (Fig 8). Moreover, with these procedures, a clear, clean gingival field is easily obtained, even when the sulcus depth is as little as 0.5 mm and when impressions must be taken of a series of teeth. Another advantage is the use of only a topical anesthetic (this must sometimes be repeated). In a great number of clinical situations anesthetic use was not needed, because by controlling the heat dispersion with cool air flow, the patients did not feel pain.

One disadvantage was the permanent tissue recession observed on the buccal aspect of the molars;

however, it could also be due to use of mechanical retraction. Other disadvantages, apart from the cost of the laser, concern the need to use protective eyewear for both patients and operator. This is easy without a magnifying device or with a microscope, but it is not easy with magnifying loupes. Moreover, there is a problem with the tip of the handpiece that guides the fiberoptic, so while working on the posterior teeth, it is necessary to have rounded tips that guide the fiberoptic of the lasers. However, when using the 300- μm fiber, it is not possible to use metallic tips because they overheat. Therefore, plastic tips (Black mini tips, Ultradent; South Jordan, UT, USA) were used but straightened after a few minutes of work. For correct function, it is very important to control the light spot of the laser. It must be perfectly round; otherwise the action of the laser irradiation will produce both excessive heat dispersion and a larger area of necrosis and tissue coagulation. If the light spot is not round, the fiberoptic must be cut. To correctly cut the fiberoptic, it was carved with a specific sharp instrument and then broken with two fingers, obtaining in this way a perfect section.

CONCLUSIONS

The use of Nd:YAG laser is highly desirable for accurate impression taking in situations with multiple abutments. This preliminary study revealed that the laser performance was suitable with a vulnerable width or thickness of adherent gingival tissue. Further investigations about the use of laser in the buccal region are needed, as insufficient data were available at the end of this first clinical evaluation, and also because it is necessary to study more thoroughly the laser's effects without the mechanical retraction method. The Nd:YAG laser may be used as a retraction device, because it is easy to create gingival retraction around the teeth using this device. Nevertheless, in this study the laser was used together with mechanical methods of gingival displacement to try to minimize gingival damage and to obtain a suitable vertical and lateral gingival tissue displacement.⁵

REFERENCES

1. Reiman MB. Exposure of subgingival margins by non surgical gingival displacement. *J Prosthet Dent* 1976;36:649-654.
2. Bjorn AL, Bjorn H, Grkovic B. Marginal fit of restorations and its relation to periodontal bone level. *Odontol Revy* 1970;21:337-46.

3. Trivedi SC, Talim ST. The response of human gingiva to restorative materials. *J Prosthet Dent* 1973;29:73-80.
4. Chiche G, Pinault A. Esthetics of anterior fixed prosthodontics. Berlin: Quintessence, 1994;6:115-118.
5. De Waal H, Castellucci G. The importance of restorative margin placement to the biologic width and periodontal health. Part 1. *J Periodont Res Dent* 1993;13:461-471.
6. De Waal H, Castellucci G. The importance of restorative margin placement to the biologic width and periodontal health. Part 2. *J Periodont Res Dent* 1994;14:71-83.
7. Benson BW, Bomberg RA, Hatch MS, Hoffman W. Tissue displacement methods in fixed prosthodontics. *J Prosthet Dent* 1986;55:175-180.
8. Harrison JD. Prevention of failures in making impression and dies. *Dent Clin N Am* 1979;23:13-20.
9. Azzi CD, Tsao TF, Carranza FA, Kennedy MS. Comparative study of gingival retraction methods. *J Prosthet Dent* 1983;50:561-565.
10. La Forgia A. Mechanical-chemical and electrosurgical tissue retraction for fixed prosthesis. *J Prosthet Dent* 1964;14:1107-1114.
11. Loe H. Reaction of marginal periodontal tissues to restorative procedures. *Int Dent J* 1968;18:759-778.
12. Loe H, Silness J. Tissue reaction to string packs used in fixed restoration. *J Prosthet Dent* 1963;13:318-323.
13. Nemetz H, Donovan T, Landesman H. Exposing the gingival margin: a systematic approach for the control of hemorrhage. *J Prosthet Dent* 1984;51:647-651.
14. Piek RM. Using lasers in clinical dental practice. *J Am Dent Assoc* 1993;124:37-47.
15. Ferrari M, Crysanti Caglidaco M, Ercoll C. Tissue management with a new gingival retraction material: a preliminary clinical report. *J Prosthet Dent* 1996;75:242-247.
16. Ortensi L, Strocchi ML. Modified custom tray. *J Prosthet Dent* 2000;84:237-240.
17. Drago MR, Williams GB. Periodontal tissue reaction to restorative procedures. *Int J Perio Rest Dent* 1981;1:3-23.
18. Magne P, Belser U. Bonded porcelain restorations in anterior dentition: a biomimetic approach. Berlin: Quintessence, 2002: 274-279.
19. Hingraham R, Sochat P, Hansing FJ. Rotary gingival curettage. A technique for tooth preparation and management of the gingival sulcus for impression taking. *Int J Perio Rest Dent* 1981;1:4-9.
20. Ruel J, Schuessler P J, Malament K, Mori D. Effect of retraction procedures on the periodontium in humans. *J Prosthet Dent* 1980;40:508-518.
21. Wilhelmsen NR, Ramfjord SP, Blankenship JR. Effects of electro-surgery on the gingival attachment in rhesus monkeys. *J Periodontol* 1976;47:160-165.
22. Gilckman I, Imber LR. Comparison of gingival resection with electrosurgery and periodontal knives: a biometric and histological study. *J Periodontol* 1970;41:142-148.
23. Martelli SF, De Leo A, Zinno S. *Laser in Odontostomatologia. Applicazioni cliniche.* Ed Masson, 2000.
24. White JM, Goods HE, Rose CL. Use of the pulsed Nd:YAG laser for intraoral soft tissue surgery. *Lasers Surg Med* 1991;11:445-461.
25. Pick RM, Colverd MD. Current status of lasers in soft tissue dental surgery. *J Periodontol* 1993;64:589-602.

Contact address: Dott. Raffaello Cimma, Via N. Porpora 44, 10154 Torino, Italy. Tel./fax: +39-0112-052-724. e-mail: r.cimma@libero.it